

Orthodontic Stability of Advanced Lower Incisors Following Selective Alveolar Decortication



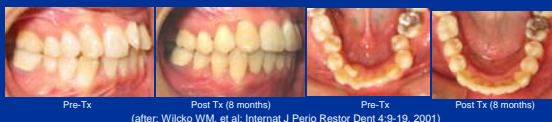K. Oliveira*, D.J. Ferguson, O. Rajaei, W.M Wilcko, & M.T. Wilcko

Boston University
Orthodontics

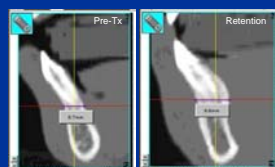
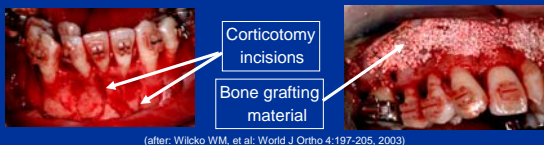


Introduction

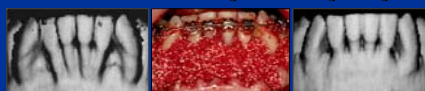Decortication-facilitated orthodontics is a relatively new technique combining braces and alveolar corticotomy plus grafting. (Wilcko, WM, et al. Internat J Perio Restor Dent 21:9-19, 2001) Dental arches are decrowded and finished in 60-70% less active orthodontic treatment time. (Wilcko WM, et al. World J Ortho 4:197-205, 2003)



Decortication is an incision made into cortical bone, and this is done after orthodontic appliances have been placed. Surgical scarring of alveolar bone induces an increase in hard & soft tissue turnover, a process collectively known as Regional Acceleratory Phenomena or RAP. (Frost HA, Orthop Clin of N Amer 12:725, 1981)



Post ortho decrowding stability likely depends on: 1) **tissue turnover** and 2) **cortical bone thickness**. Twaddle (MSD Thesis, SLU, 2002) demonstrated a stable increase in alveolar cortical bone thickness at mandibular symphysis following AAOtm and augmentation grafting.



Objectives

To assess the effects of labial advancement of lower incisors of at least 3mm on orthodontic outcome stability following selective alveolar decortication plus grafting (AAOtm).

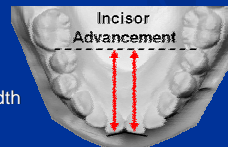
Methods & Materials

Sample

The study cast records of 75 orthodontic non-extraction adult patients treated with straight-wire mechanics were examined at pre-tx (T1), post treatment (T2) and retention (T3) and grouped as follows: L1 advanced >3mm with AAOtm (n=8), L1 advanced <3mm with AAOtm (n=16), L1 advanced >3mm without AAOtm (n=25), and L1 advanced <3mm without AAOtm (n=26).

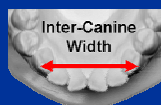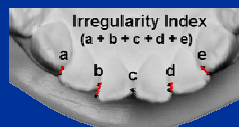
Procedure

- Lower incisor position was measured on pre-tx, post tx & retention casts. Sample was grouped for > 3mm or < 3mm advancement.
- Irregularity Index and Inter-canine width was measured at T1, T2 and T3.



Data of Interest:

- Irregularity Index
- Inter-Canine Width



Results

Irregularity Index

@ Pre-Tx: Homogeneous (p>.05)

@ Post Tx: Homogeneous (p>.05)

@ Retention:

- Both AAOtm group had significantly less (p=.002) irregularity than the both groups without AAOtm

Irregularity NDX	T1	T2	T3
<3mm n=26	5.4	0.4	2.6
>3mm n=25	5.2	0.3	4.4
<3mm AAO tm n=16	4.3	0.5	0.8
>3mm AAO tm n=8	7.8	0.7	1.3

Irregularity Index Change

- Both AAOtm groups relapsed (p<.001) significantly less during retention

Irreg NDX Change	T1-T2	T2-T3
<3mm n=26	5.0	-2.2
>3mm n=25	4.9	-4.1
<3mm AAO tm n=16	1.1	-0.3
>3mm AAO tm n=8	4.4	-0.5

Inter-Canine Width Change

- No differences in 3-3 tx changes
- < 3mm AAOtm group relapsed (p<.001) significantly less during retention

3-3 Width Change	T1-T2	T2-T3
<3mm n=26	1.0	-1.4
>3mm n=25	0.9	-1.7
<3mm AAO tm n=16	0.6	-0.3
>3mm AAO tm n=8	0.1	-0.6

Conclusion

Advancement of the lower incisors greater than 3mm did not result in significant re-crowding when selective alveolar decortication and grafting was combined with orthodontic treatment; **relapse was absent**. Incisor stability is likely due to tissue memory after dramatically increased tissue turnover, and increased thickness of alveolar cortical bone from the augmentation grafting.